

# The Underlying Anatomy of Vitreous and Its Role in Retinal Disease

BY J. SEBAG, MD, FACS, FRCOPHTH, FARVO

Vitreous is a remarkable structure. It is 98% water, but owing to the 2% structural macromolecules, vitreous maintains an exquisite gel structure.

Those structural macromolecules are hyaluronan, which is a glycosaminoglycan of repeating disaccharide units, and collagen. Because hyaluronan is very hydrophilic and absorbs water, where it goes, water follows. Hyaluronan is also organized within an entangled network that creates viscoelasticity, an important biophysical property. Collagen is the “skeleton” of the vitreous body. The most prevalent subtype of collagen that comprises the human vitreous is type II. The only other place in the human body that type II collagen is found abundantly is the articular cartilage in the joints. In both the joints and vitreous, there are many simultaneous manifestations of inborn congenital errors. An organization of collagen and hyaluronan exists within the vitreous, so that the collagen fibrils are spread apart by the hyaluronan molecules, maximizing the number of photons that penetrate the vitreous and access the retina, where vision begins.<sup>1</sup>

## VITREOUS AGING

We have studied vitreous structure using dark-field slit-lamp microscopy. Figure 1 shows the appearance of the vitreous from a 33-week-old week old human embryo. There are no visible structures within the vitreous body, except for the remnant of Cloquet’s canal, which is oriented toward the prepapillary posterior vitreous cortex. By middle age (Figure 2A), there are fibers within the vitreous body that have an anterior-posterior orientation arising from the vitreous base, and coursing posteriorly to insert into the posterior vitreous cortex. By old age (Figure 2B), these fibers have become aggregated and tortuous and are associated with pockets of liquefied vitreous.<sup>2,3</sup>

Transmission electron microscopy has demonstrated that these fibers consist of parallel collagen fibrils organized in bundles. It was previously thought that collagen fibrils inserted directly into the retina, but we now know that there is an extracellular matrix interface that mediates the vitreous adherence to the retina, which can be targeted by pharmacologic vitreolysis.

The outer vitreous is organized in sheets, or lamellae. These lamellar sheets are important, as they represent potential cleavage planes that occur either during aging

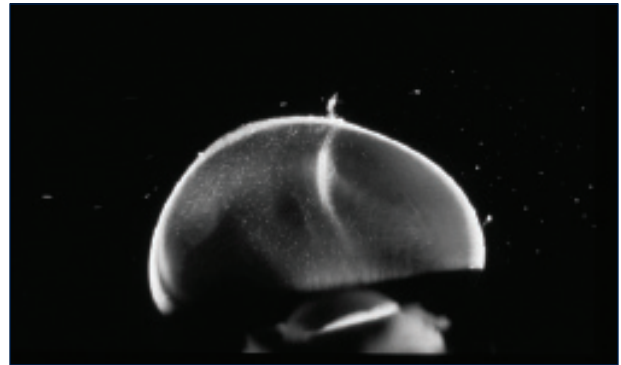


Figure 1. The appearance of the vitreous from a 33-week-old week old human embryo.

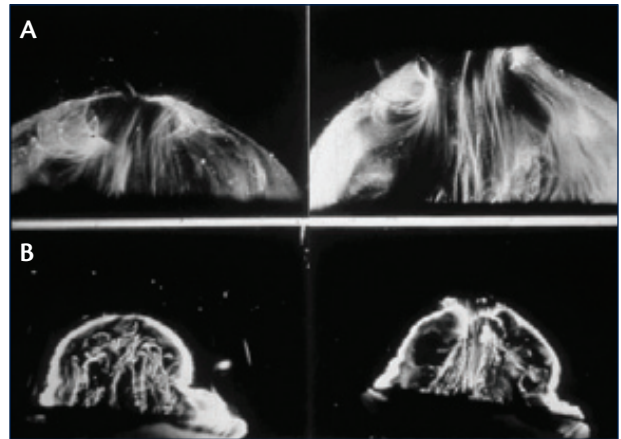


Figure 2. By middle age, there are fibers within the vitreous body that have an anterior-posterior orientation arising from the vitreous base, and coursing posteriorly to insert into the posterior vitreous cortex (A). By old age, these fibers have become aggregated and tortuous and are associated with pockets of liquefied vitreous (B).

and posterior vitreous detachment (PVD), or during surgically induced PVD. Such a split is called vitreoschisis, an important manifestation of anomalous PVD.

## THE MECHANISM OF POSTERIOR VITREOUS DETACHMENT

The underlying anatomy of the vitreous is important to keep in mind when considering disease of the vitreomacular interface (VMI) and how to approach treatment. Although

Figure 2 reprinted with permission from Sebag J. Age-related changes in human vitreous structure. *Grader's Arch Clin Exp Ophthalmol*. 1987;25(2):89-93. Copyright 1987. With kind permission from Springer Science and Business Media

Q&A WITH ANSELM KAMPIK, MD; J. SEBAG, MD; AND RAMIN TADAYONI, MD

**Anselm Kampik, MD:** Does the vitreous have the same molecular structure as the cornea?

**J. Sebag, MD:** Yes. In fact, the molecular constituents of the cornea and vitreous are the same. The difference is in hydration: To work well, the cornea requires dehydration but vitreous requires hydration.

**Dr. Kampik:** Is the collagen type of the zonules the same as in the vitreous and the vitreomacular interface?

**Dr. Sebag:** No. The zonular fibers are made of elastin, which is a different protein than the collagen structure of the vitreous. This is why ocriplasmin injections do not result in lens dislocation.

**Dr. Kampik:** How do you quantify metamorphopsia?

**Ramin Tayadoni, MD, PhD:** There is no good way to quantify metamorphopsia—we can only rely on the patient's subjective reports. It is rare, however, that a patient will describe metamorphopsia with no decrease in vision.

**Dr. Sebag:** We are working with a new method to quantify metamorphopsia with 3D threshold Amsler grid testing and 2009 published our findings in macular edema from AMD and DME in *Graefe's Archive for Clinical and Experimental Ophthalmology*, in 2011 for distinguishing wet from dry AMD in the *British Journal of Ophthalmology*, and in 2013 in *Retina* quantified the response of VMT treated by pharmacologic vitreolysis.

**Dr. Kampik:** What is more important and would cause you to consider intervention with an injection of ocriplasmin or surgery: reduced visual acuity or metamorphopsia?

**Dr. Tayadoni:** If a patient has good visual acuity but metamorphopsia, I would be hesitant to do surgery. There is no guarantee a patient will have good vision after surgery. I present the risks and have patients think it over before making any decisions.

**Dr. Sebag:** At the end of the day, we are in the business of happiness. The worst thing you can do to a happy patient is to make them unhappy by doing something from which they will not benefit since they were not unhappy to begin with. The secret is to identify your unhappy patients, try to understand the source of their unhappiness, and help them based upon their expectations.

**Dr. Kampik:** This is an important point. We do not treat symptoms or OCT findings, but patients. How do you measure the size of the macular hole on SD-OCT? Is it the same? Is it different? And what are the other criteria you are looking for on OCT?

**Dr. Tayadoni:** It is easier with SD-OCT, because it is easier to use calipers to measure from the scans that can be taken around the area of the hole and we are able to choose a scan where the hole is widest or most narrow.

we know that aging changes the VMI, it remains unclear as to exactly how vitreous adheres to retina. However, we do know that the vitreous is firmer during youth than later in life.<sup>3</sup> The source of the adhesion remains partially unclear, but is an important consideration in the design of agents to induce PVD.

PVD is the most common event in the life of the human vitreous, occurring in 2 out of 3 individuals over the age of 65. It is important to remember that for a PVD to be innocuous, 2 things must happen at the same time: liquefaction of the gel and weakening at the vitreoretinal interface. When these occur in tandem, the separation

is clean and, other than some vitreous floaters, there are no untoward effects. Liquefaction without dehiscence, however, results in anomalous PVD. The manifestations of anomalous PVD vary, depending upon where the gel is most liquefied and where the vitreous is most firmly adhered to the retina.

In 2004 I proposed the notion of anomalous PVD as a unifying concept of various disparate diseases ranging from retinal tears and detachments to macular holes and pucker. These were previously considered to be very different disease states, but when considered from the perspective of anomalous PVD, one can begin to

understand how these are various manifestations of the same underlying problem.

When liquefaction occurs with separation of the peripheral vitreous but persistent adhesion of full thickness posterior vitreous cortex to the macula, axial traction in an anterior-posterior direction can result, which plays an important role in VMT syndrome, such as in this extreme case in Figure 3, where combined scanning laser ophthalmoscopy (SLO)/optical coherence tomography (OCT) imaging shows elevation of the central macula by vitreous that has separated peripherally, but that has remained adherent to the macular region.

**ANOMALOUS POSTERIOR VITREOUS DETACHMENT AND RETINAL DISEASE**

Anomalous PVD can also influence wet age-related macular degeneration (AMD). The previous belief was that 3 out of 4 elderly patients had already undergone PVD, since they were all elderly. However, Susanne Binder, MD, made the observation that in cases for which she performed submacular surgery to remove choroidal neovascularization (CNV), which was a more common practice in the past, a high proportion of patients' vitreous was still attached to the macula (83%).<sup>4</sup> To corroborate this, we performed a study using ultrasound to diagnose total PVD and OCT to diagnose vitreomacular adhesion (VMA).<sup>5</sup> We found a 2-fold higher prevalence of total PVD, as diagnosed by ultrasound, in patients who had dry AMD, as compared to controls in patients who had wet AMD. By OCT, there was a four-fold higher incidence of VMA in wet AMD as compared to dry AMD.

Another manifestation of anomalous PVD is vitreoschisis—splitting of the posterior vitreous cortex, in which the outer layer of vitreous remains adherent to the macula while the rest of the vitreous pulls away. The remnant layer can cause tangential traction on the macula. This may play an important role in macular pucker and macular hole. In fact, we performed a study where vitreoschisis was identified in approximately half

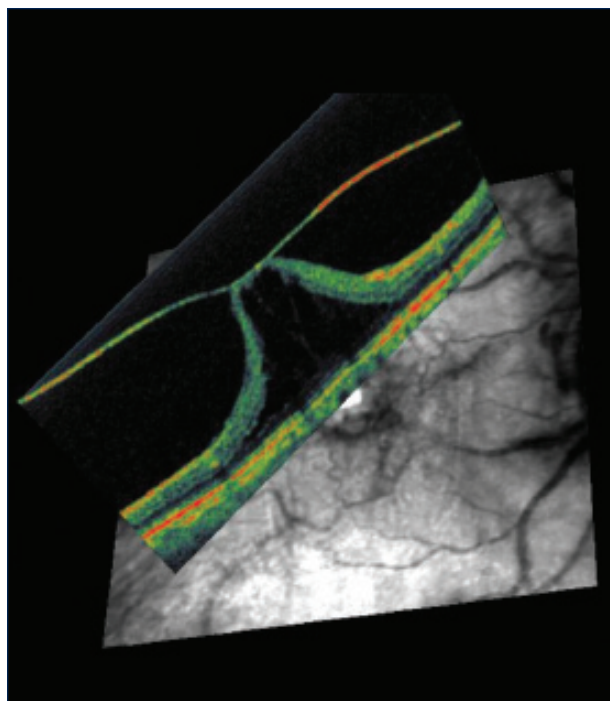


Figure 3. VMT syndrome. Combined scanning laser ophthalmoscopy (SLO)/optical coherence tomography (OCT) imaging shows elevation of the central macula by vitreous that has separated peripherally, but that has remained adherent to the macular region.

of patients with macular pucker or full-thickness macular holes (FTMH).<sup>6,7</sup>

An important characteristic of FTMH is persistent vitreopapillary adhesion to the optic disc, found in 87.5% of cases.<sup>8</sup> This likely causes the tangential forces in a macular hole to be opposite that of macular pucker, where the incidence of vitreopapillary adhesion is 17.9%. The layer that is still attached in macular pucker contracts inward (centripetally), rippling the macula. In FTMH, the forces are outward, (centrifugally) opening a dehiscence in the central macula and creating a hole.

**TABLE 1. INTERNATIONAL VITREOMACULAR STUDY (IVTS) GROUP CLASSIFICATION 2013**

Classification	Sub-Classification
Vitreomacular Adhesion (VMA)	focal ( $\leq 1500 \mu\text{m}$ ) or broad ( $> 1500 \mu\text{m}$ ) isolated or concurrent with other diseases No structural abnormalities in retina
Vitreomacular Traction (VMT)	focal ( $\leq 1500 \mu\text{m}$ ) or broad ( $> 1500 \mu\text{m}$ ) isolated or concurrent with other diseases + structural abnormalities in macula
Full-Thickness Macular Hole (FTMH)	small ( $\leq 250 \mu\text{m}$ ), medium ( $> 250 \mu\text{m}$ and $\leq 400 \mu\text{m}$ ), or large ( $> 400 \mu\text{m}$ ) with or without VMT primary or secondary to other conditions

**NEW CLASSIFICATION SYSTEM FOR VITREOMACULAR INTERFACE DISORDERS**

The increased knowledge that has emerged regarding the vitreous allowed for the 2013 introduction by an international panel of a new classification system.<sup>9</sup> The principles behind the classification system include the following: (1) that it be strictly anatomic (ie, based upon OCT); (2) that it be based on symptoms and not based on clinical findings; (3) that it be simple and easy to use; and (4) that it be predictive of outcomes both with surgery or pharmacologic vitreolysis.

The classifications and subclassifications are seen in Table 1. The classifications are divided into 3 categories: VMA, VMT, and FTMH. VMA is subclassified as focal ( $\leq 1500 \mu\text{m}$ ) or broad ( $> 1500 \mu\text{m}$ ), isolated or concurrent with other diseases, and without structural abnormalities. VMT is subclassified as either ( $\leq 1500 \mu\text{m}$ ) or broad ( $> 1500 \mu\text{m}$ ), isolated or concurrent with other diseases, and with structural abnormalities in the macula. FTMH is subclassified into small ( $\leq 250 \mu\text{m}$ ), medium ( $> 250 \mu\text{m}$  and  $\leq 400 \mu\text{m}$ ), large ( $> 400 \mu\text{m}$ ), with or without VMT, and primary or secondary to other conditions.

It is with this classification system that we hope to identify patients who will benefit from interventional procedures to manage disorders of the vitreous. ■

*J. Sebag, MD, FACS, FRCOphth, FARVO, is a Professor of Clinical Ophthalmology at the Doheny Eye Institute in Los Angeles and the Founding Director of the VMRI Institute in Huntington Beach, CA. He may be reached at [jsebag@VMRIinstitute.com](mailto:jsebag@VMRIinstitute.com).*



1. Bishop PN. Structural macromolecules and supramolecular organisation of the vitreous gel. *Prog Retin Eye Res.* 2000;19(3):323-344.
2. Sebag J, Balazs EA. Morphology and ultrastructure of human vitreous fibers. *Invest Ophthalmol Vis Sci.* 1989;30(8):1867-1871.
3. Sebag J. Age-related changes in human vitreous structure. *Graefes Arch Clin Exp Ophthalmol.* 1987;225(2):89-93.
4. Binder S, Krebs I, Hilgers RD, et al. Outcome of transplantation of autologous retinal pigment epithelium in age-related macular degeneration: a prospective trial. *Invest Ophthalmol Vis Sci.* 2004;45(11):4151-4160.
5. Krebs I, Brannath W, Glittenberg C, Zeiler F, Sebag J, Binder S. Posterior vitreomacular adhesion: a potential risk factor for exudative age-related macular degeneration? *Am J Ophthalmol.* 2007;144(5):741-746.
6. Sebag J, Gupta P, Rosen RR, Garcia P, Sadun AA. Macular holes and macular pucker: the role of vitreoschisis as imaged by optical coherence tomography/scanning laser ophthalmoscopy. *Trans Am Ophthalmol Soc.* 2007;105:121-129; discussion 129-131.
7. Gupta P, Yee KMP, Garcia P, et al. Vitreoschisis in macular diseases. *Br J Ophthalmol.* 2011;95(3):376-380.
8. Wang MY, Nguyen D, Hindoyan N, Sadun AA, Sebag J. Vitreo-papillary adhesion in macular hole and macular pucker. *Retina.* 2009;29:644-550.
9. Duker JS, Kaiser PK, Binder S, et al; The International Vitreomacular Traction Study Group. Classification of vitreomacular adhesion, traction, and macular hole. *Ophthalmology* 2013;120(12):2611-2619.