

# Morphology and Ultrastructure of Human Vitreous Fibers

J. Sebag\*† and E. A. Balazs†

**Significant alterations in vitreous structure occur with aging and disease. There is controversy as to the nature of the normal structure of the vitreous and no studies have correlated macroscopic structure with ultrastructure in the same eyes. Twenty-eight fresh, untreated human eyes were examined after removal of the sclera, choroid and retina. Dark-field slit illumination of the whole vitreous revealed the presence of macroscopic fibrous structures. The fibers had an antero-posterior orientation with anterior insertions at the vitreous base and posterior insertions in the premacular vitreous cortex. Transmission electron microscopy demonstrated the presence of collagen fibrils and no membranous structures. Parallel collagen fibrils packed in bundles were also detected. Macroscopic vitreous fibers most likely result from alteration of the hyaluronic acid-collagen complex with aggregation of collagen fibrils into bundles as seen on electron microscopy. Identifying the mechanisms underlying this process of fiber formation could clarify the pathogenesis of vitreous liquefaction and the pathophysiology of posterior vitreous detachment. Invest Ophthalmol Vis Sci 30:1867-1871, 1989**

According to Duke-Elder,<sup>1</sup> the mid-eighteenth century marked the first attempts at describing vitreous structure, when Demours and Zinn proposed the concept that the vitreous is a framework of "loose and delicate filaments enclosing spaces filled with humor." In the mid-nineteenth century various tissue fixatives were used to visualize vitreous structure histologically. Bowman<sup>2</sup> pointed out that these studies were flawed by artefacts due to fixation-induced precipitation of hyaluronic acid. Around the turn of the twentieth century histologic investigations<sup>3,4</sup> led to the conclusion that vitreous was composed of a framework of fibers forming a net enclosing a fluid in its meshes, but these results were also influenced by fixative artefact.

The introduction of slit-lamp biomicroscopy enabled ophthalmologists to examine the vitreous in vivo, devoid of histologic artefacts. However, some examiners saw membranes<sup>5</sup> and bands,<sup>6</sup> while others saw fibers,<sup>7</sup> and still others saw layers of fibers,<sup>8</sup> or sheets.<sup>9</sup> Eisner<sup>10</sup> used slit-lamp examination of dissected human autopsy eyes, and described a system of "membranelles" he called "tractae" that course from the posterior pole and insert anteriorly between the ora serrata and the edge of the lens.

The study presented herein has attempted to elucidate the structure of the adult human vitreous using dark-field illumination of untreated, dissected specimens of whole vitreous and correlating the results with ultrastructural studies of the same specimens. The objectives were to characterize adult human vitreous structure macroscopically and ultrastructurally and determine whether human vitreous contains fibers or membranes.

## Materials and Methods

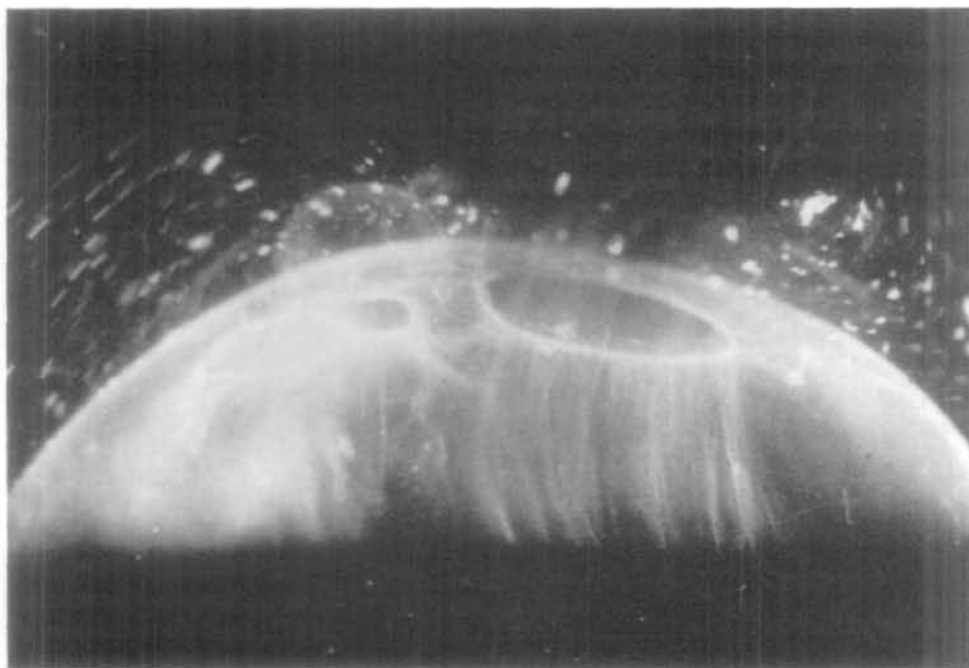Human eyes were obtained from the New York Eye Bank for Sight Restoration. Only eyes from patients who had no ocular disease or surgery and no history of diabetes, connective tissue or hematologic disorders were examined. Donors were all older than 30 with most ranging from 50-70 years of age. The time elapsed since death ranged from 12-36 hr. Following enucleation, eyes were maintained at 4°C in a moist chamber.

Eyes were mounted on a lucite frame by placing four 4-0 silk sutures through the region of the limbus. The insertions of the extraocular muscles were used as guides to orient the eyes in approximately their in vivo positions. The specimens were then immersed in isotonic saline. Scissors and forceps were used to remove most of the sclera, leaving a small area about the optic nerve. The choroid and retina were successively removed by gently applying shearing forces with two pairs of Colibri forceps. By this stage of the dissection, the optic nerve and peripapillary choroid and retina had usually separated from the posterior vitreous.

From the \*Eye Research Institute of Retina Foundation, Harvard Medical School, Boston, Massachusetts, and the †College of Physicians and Surgeons, Columbia University, New York, New York.

Submitted for publication: November 15, 1988; accepted January 17, 1989.

Reprint requests: J. Sebag, MD, 8th Floor Suite, Pacifica Tower, 18800 Delaware Street, Huntington Beach, CA 92648.



**Fig. 1.** Posterior vitreous from a 52-year-old male, 36 hr postmortem. The pre-macular (larger and to the right) and prepapillary holes are seen in the posterior vitreous cortex. In this specimen the prepapillary hole measured approximately 1.5 mm in diameter and the premacular hole approximately 5 mm in diameter. Intravitreal fibers are seen oriented to the premacular region (approximate magnification  $\times 7$ ). Reprinted with permission from ref. 16.

Mounted, dissected eyes were then placed into a lucite chamber containing isotonic saline solution. Immediate examination of the preparation was performed in a dark room with a dissecting microscope. The only light source was a horizontal slit-lamp beam shown from the side through the vitreous at an angle of  $90^\circ$  to the line of sight from above. The illuminated portion thus represented an optical horizontal section through the vitreous. Photographs were obtained by mounting a camera on top of the dissecting microscope and using Polaroid 107 film with ASA 3000.

After examination and photography the intact vitreous was fixed overnight with 3% glutaraldehyde in Erle's buffer at  $4^\circ\text{C}$ . Areas of interest within the vitreous were cut out with forceps and small scissors. Samples were centrifuged in Erle's buffer at 50,000 g for 2 hr. The pellet was then fixed in osmium tetroxide in Erle's buffer for 60 min at  $4^\circ\text{C}$ . Dehydration in alcohol was followed by embedding in Epon for transmission electron microscopy.

## Results

Dissected specimens had an intact vitreous enveloped by the vitreous cortex. There were two sharply defined circular areas in the posterior vitreous where the cortex was not present (Fig. 1). These two areas looked like "holes" in the premacular and prepapillary vitreous cortex. The premacular hole was always larger than the prepapillary hole. Vitreous was seen extruding through these holes to varying degrees.

When using a slit lamp to illuminate a horizontal

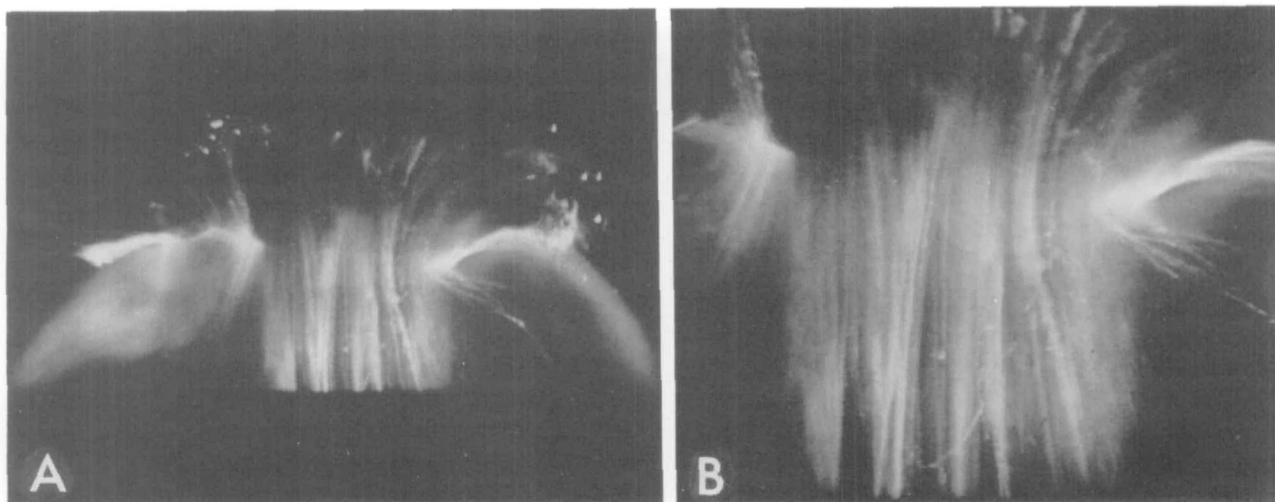
section through the vitreous, fibrous structures were observed within the vitreous. Figure 2A shows the appearance of these structures as they pass from the central vitreous to the posterior vitreous and out the premacular hole in the posterior vitreous cortex. A higher magnification (Fig. 2B) clearly demonstrates the fibrous nature of these structures.

The vitreous fibers coursed in an antero-posterior direction through the central vitreous. Their appearance did not change with rotation about the antero-posterior axis of the eye. Raising or lowering the level of the optical horizontal section (slit-lamp beam) did not give the impression that the fibers were part of a membrane being illuminated in cross-section. Instead, other fibrous structures appeared at various levels. As the optical sections approached the peripheral vitreous, fibers could not be seen clearly.

Figure 3A shows a fiber coursing posteriorly and inserting into the rim of the premacular hole in the vitreous cortex. Figure 3B shows this attachment in higher magnification. It can be seen that extrusion of vitreous out the premacular hole placed traction on this fiber. Yet, due to its attachment to the vitreous cortex at the rim of the premacular hole, the fiber arched back to its insertion.

Anteriorly, the fibers oriented towards the periphery where they inserted into the vitreous base. Figure 4 shows that the fibers splay out to insert both anterior and posterior to the ora serrata.

Transmission electron microscopy demonstrated that the vitreous contained randomly oriented collagen fibrils. Also present were bundles of parallel collagen fibrils (Fig. 5). In no specimens were membranous structures detected.



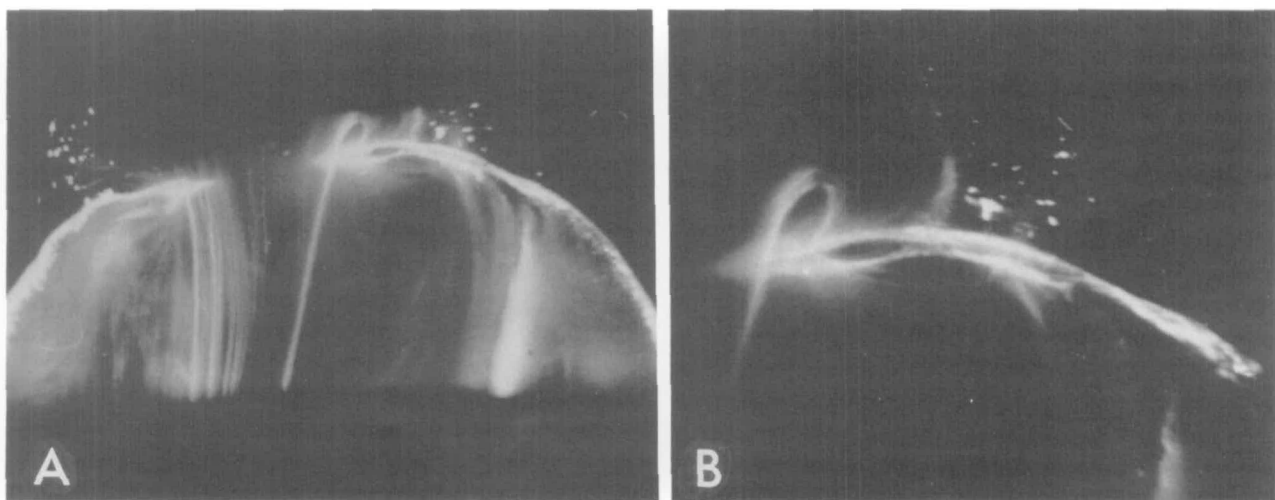
**Fig. 2.** Posterior vitreous of a 57-year-old male 30 hr postmortem. (A) Fibers are seen coursing from the central and posterior vitreous through the premacular hole. The posterior extrusion of vitreous draws the fibers into the retrovitreal space (approximate magnification  $\times 4.5$ ). (B) The linear, highly oriented nature of the fibers can be seen at a higher magnification (approximately  $\times 9$ ).

### Discussion

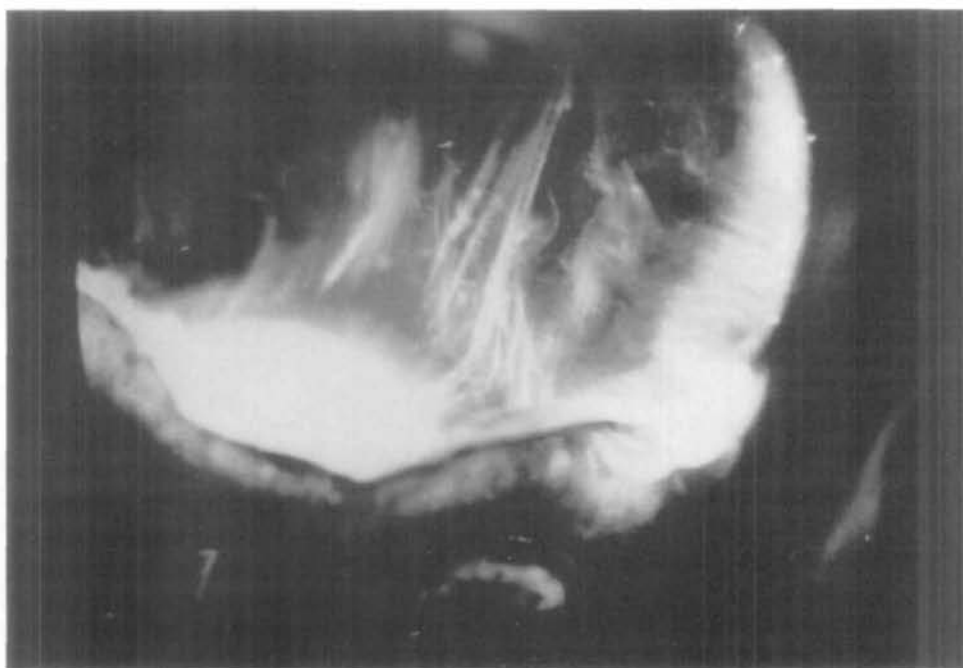This study demonstrates that the normal vitreous of adult middle-aged humans contains linear fibers and no membranous structures. These fibers have an antero-posterior orientation. Anteriorly, the fibers insert into the vitreous base. Posteriorly, fibers appear to insert into the vitreous cortex overlying the macula. The factors accounting for the visualization of vitreous structure achieved in this study are primarily the maintenance of vitreous turgescence, the sagittal tension placed upon the vitreous and the use of an illumination-observation angle of  $90^\circ$  that maximizes the Tyndall effect. There is no ultrastructural element in the human vitreous that could correspond

to these fibers, other than collagen fibrils.<sup>11,12</sup> Transmission electron microscopy confirmed the absence of membranes and showed that the macroscopic fibrous structures consist of packed bundles of parallel collagen fibrils.

It could be argued that traction due to mechanical removal of the retina and extrusion of the vitreous into the retrohyaloid space resulted in the appearance of the fibers and their orientation to the macula. It is true that in vivo the macroscopic fibers of the vitreous do not have the "taut" appearance of the fibers as observed in vitro. This in vitro appearance nonetheless reflects the intrinsic fibrous structure, perhaps somewhat exaggerated by the sagittal tension exerted by posterior vitreous extrusion. Studies<sup>13</sup> of special



**Fig. 3.** Posterior vitreous of a 53-year-old female 26 hr postmortem. (A) In the central and posterior vitreous there are fibers oriented antero-posteriorly, adjacent to extensive central liquefaction (approximate magnification  $\times 4.5$ ). (B) Higher magnification (approximately  $\times 9$ ) shows the insertion of a well defined fiber into the posterior vitreous cortex near the rim of the premacular hole. The curved appearance is due to the posterior traction of the extruding vitreous which pulls on the fiber that is still attached to the posterior vitreous cortex. Reprinted with permission from ref. 16.



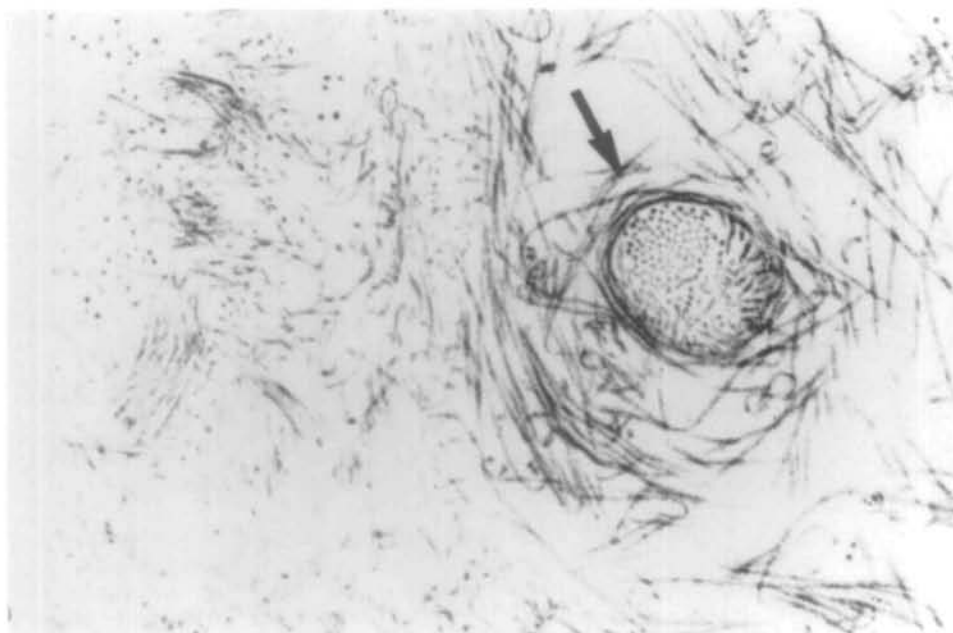
**Fig. 4.** Central and anterior vitreous with view of posterior lens in the same specimen as Figure 2. Fibers are in an antero-posterior orientation. As they course forward towards the lens they splay out to insert into the vitreous base both anterior and posterior to the ora serrata (approximate magnification  $\times 6$ ).

preparations with an intact posterior pole and no ret-rohyaloid extrusion showed that even in the absence of traction, the fibers were still visible and did orient towards the macula. Furthermore, the observation in the current study of a fiber actually inserting into the posterior vitreous cortex at the rim of the premacular hole supports the concept of premacular orientation and insertion.

Based upon the macroscopic appearance of the vitreous fibers, the ultrastructural findings of parallel collagen fibrils arranged in bundles, and previous reports,<sup>14-16</sup> we hypothesize that these fibers represent

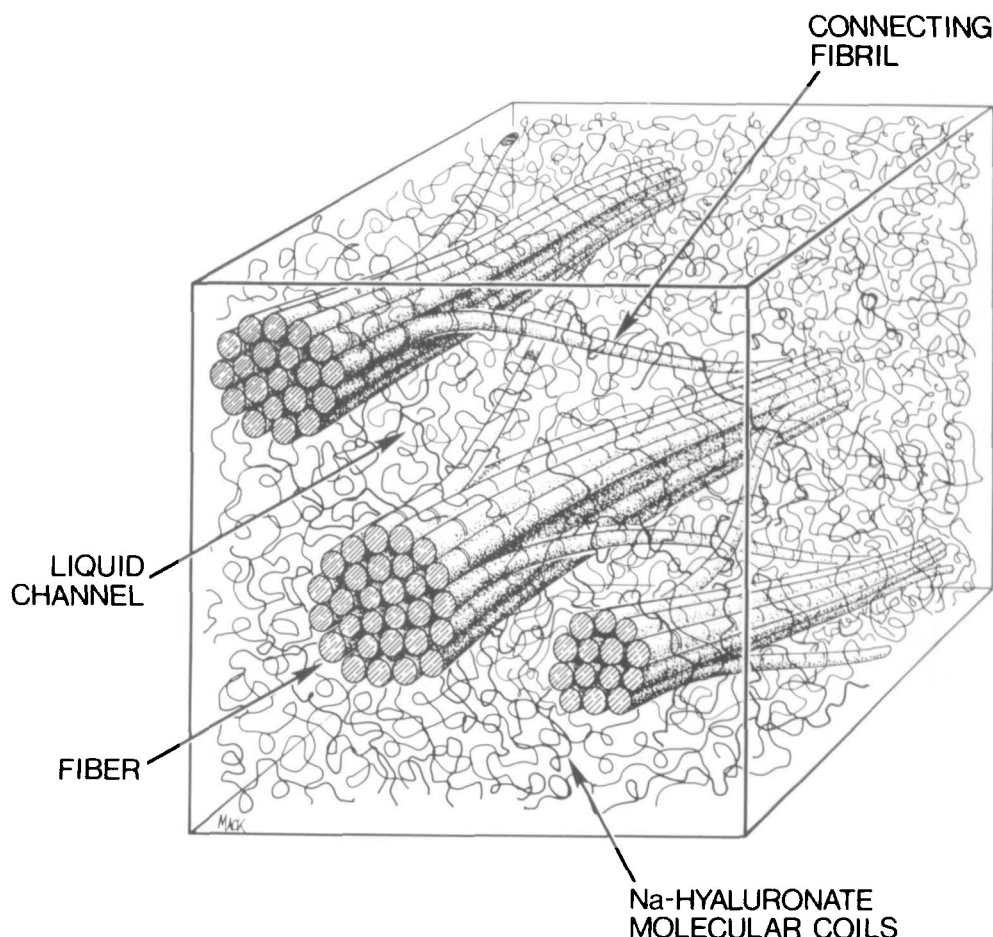
aggregates of parallel collagen fibrils that were previously randomly oriented. The large hyaluronic acid (HA) molecules that previously separated the collagen fibrils are now excluded from these aggregates and most likely fill the spaces between the packed bundles of fibrils, entangled with a loose network of nonoriented collagen fibrils (Fig. 6).

The process that forms these fibers is not known. It may involve dissociation of HA molecules from collagen fibrils and segregation of the HA into pools that ultimately form lacunae, while the collagen fibrils aggregate into parallel bundles and form fibers. This



**Fig. 5.** Transmission electron micrograph of a specimen taken from the central vitreous of the eye shown in Figure 1. Collagen fibrils are packed into a bundle of parallel fibrils seen in cross-section (arrow) (approximate magnification  $\times 45,000$ ).

**Fig. 6.** Schematic diagram of adult human vitreous ultrastructure. Parallel collagen fibrils are packed into bundles that aggregate and ultimately form visible fibers. Hyaluronic acid and water molecules fill the interfibrillar spaces.



process is likely to be related to liquefaction of the vitreous and thus contribute to the development of posterior vitreous detachment (PVD). Elucidating the molecular mechanisms underlying these events may lead to a better understanding of the phenomenon of PVD and possibly the development of methods by which vitreous detachment can be inhibited or induced, depending upon the clinical circumstances and the desired effect.

**Key words:** human vitreous, morphology, ultrastructure, hyaluronic acid, collagen

### Acknowledgments

These investigations were undertaken as a result of initial observations by Mr. Patrick Freyne, formerly of the New York Eye Bank for Sight Restoration. The assistance of Ms. H. Kjeldbye, Dr. B. Stein, Dr. Mary Flood and Ms. Lynda Morgan is also appreciated.

### References

1. Duke-Elder WS: The nature of the vitreous body. *Br J Ophthalmol* 14(Monogr Suppl 4):6, 1930.
2. Bowman W: Observations on the structure of the vitreous humor. *Dublin Quart J Med Sci* VI:102, 1884.
3. Retzius: Om membrana limitans retinae interna. *Nordiskt Archiv* III(2):1, 1874.
4. Szent-Gyorgyi A: Untersuchungen über den bau des glaskörpers des menschen. *Arch für Mikr Anat* 89:324, 1917.
5. Gullstrand A: Die nernspaltlampe in der ophthalmologischen praxis. *Klin Monatsbl Augenheilkd* 50:483, 1912.
6. Koeppe L: Clinical observation with the slit lamp. *Arch F Ophthal Bd XCIV and XCVI*:232, 1917.
7. Baumann M: Über die Beziehungen der ultramikroskopischen glaskörperstruktur zu den spaltlampenbefunden. *Graefes Arch Ophthalmol* 117:304, 1926.
8. Goedbloed J: Studien am Glaskörper: I. Die struktur des glaskörpers. *Graefes Arch Ophthalmol* 323, 1934.
9. Friedenwald JF and Stiehler RD: Structure of the vitreous. *Arch Ophthalmol* 14:789, 1935.
10. Eisner G: *Biomicroscopy of the Peripheral Fundus*. New York, Springer-Verlag, 1973.
11. Matoltsky AG, Gross J, and Grignolo A: A study of the fibrous components of the vitreous with the electron microscope. *Proc Soc Exp Biol Med* 76:857, 1951.
12. Schwarz W: Elektronenmikroskopische untersuchungen über die Glaskörperstrukturen im rinderauge. *Z Zellforsch* 36:45, 1951.
13. Sebag J: Age-related changes in human vitreous structure. *Graefes Arch Clin Exp Ophthalmol* 225:89, 1987.
14. Balazs EA: Molecular morphology of the vitreous body. *In* *Structure of the Eye*, Smelser GK, editor. New York, Academic Press 1961, pp. 293-310.
15. Sebag J and Balazs EA: Human vitreous fibres and vitreoretinal disease. *Trans Ophthalmol Soc UK* 114:123, 1985.
16. Sebag J and Balazs EA: Pathogenesis of CME: Anatomic considerations of vitreo-retinal adhesions. *Surv Ophthalmol* 28 (Suppl):493, 1984.